



**PATIENT**

Brim Murray

**SPECIES**

Feline

**BREED**

DSH

**SEX**

Male Neutered

**AGE**

8.10 years

**WEIGHT**

14.58lbs

**INTERPRETED BY**

Maggie Machen Lamy,  
DVM, DACVIM  
(Cardiology)

**IMAGING PERFORMED BY**

Ashley Whitesell

**HOSPITAL NAME**

Dicksib Animal Clinic

**REFERRING VET**

Dr. Hovis

**INVOICE**

46304

**DATE**

1/6/26

**PRESENTING CLINICAL SIGNS**

History: Asthma; treated with Albuterol, Fluticasone, and Prednisone. Sedated with Bonqat. BP: 139mmHg.

**ECHOCARDIOGRAM FINDINGS**

2D, m-mode, color flow and doppler imaging is available. The left ventricular wall is mildly increased in dimension. There is a diffusely hyperechoic endocardium consistent with fibrosis. Mild symmetric papillary muscle hypertrophy and remodeling. The right ventricle is subjectively normal in size and morphology. There is no left atrial enlargement present. No right atrial enlargement present. Normal RVOT velocity. Trace TR. There is no obvious systolic anterior motion (SAM) of the mitral valve present. No MR. No significant AI or PI. There is no pericardial effusion noted. No pleural effusion appreciated. No obvious cardiac tumors.

**CARDIAC CHART**

| FELINE CARDIAC PARAMETERS | BODY WEIGHT (kg) | HR (BPM)                        | IVSd (cm) (Moise, Pipers)                | LVIDd (cm) (Moise, Pipers) | LVWd (cm) (Moise, Pipers) | FS (%)         | EF (%)      |
|---------------------------|------------------|---------------------------------|--|----------------------------|---------------------------|----------------|-------------|
| NORMAL PARAMETER          | -----            | 150-240                         | 0.35-0.55                                | <2 (mean 1.5)              | 3.5-0.55                  | 35-67          | 80-100      |
| PATIENT                   | 6.6              | NM                              | 0.65                                     | 1.2                        | 0.63                      | 58             | 90          |
| FELINE CARDIAC PARAMETERS | LA/AO (Boon)     | LA/AO HEART BASE (Swe) (Abbott) | LA 2D short axis Base view (cm) (Abbott) |                            | LVOT VEL (m/s)            | RVOT VEL (m/s) | E max (m/s) |
| NORMAL                    | <1.5             | <1.3                            | <1.2                                     |                            | <1.6                      | <1.3           | <0.9        |
| PATIENT                   | NM               | 1.4                             | 1.3                                      |                            | NM                        | 1.6            | NM          |

*\*Note: All measurements based upon multi-modal images and methods. An average value is reported.  
Adapted from June Boon, Veterinary Echocardiography, 1998  
Abbott J & MacLean H JVIM 2006;20: 111-119, Moise et al. Am J Vet Res 47:1476, 1986. Pipers et al. Am J Vet Res 40:882, 1979.*

**INTERPRETATION OF THE FINDINGS & FURTHER RECOMMENDATIONS**

Hypertrophic cardiomyopathy (HCM) is a rule out diagnosis once a patient is deemed normotensive and euthyroid. The BP is normal; however, a thyroid status should be assessed. Regardless, the degree of disease is mild, with only mild LVH and no LA dilation. This would indicate the risk for clinical issues is low at this time. Flow through the great vessels is normal, and no significant valve regurgitation is seen. No additional pathology is identified.

No medications are indicated prior to significant atrial dilation. It is important to note that no medications have been shown to definitively alter long term outcome at this stage, particularly in the absence of SAM.

Prognosis is guarded, given the highly variable rates of progression with subclinical feline cardiomyopathy. Many cats will remain asymptomatic for a period of years, while others progress to clinical compromise sooner. Close monitoring for progressive LA dilation in the future will help determine long term outcome.

Monitor at home for any respiratory issues or signs of blood clot events (neurologic change, paralysis, etc.).



## PATIENT

Brim Murray

## SPECIES

Feline

## BREED

DSH

## SEX

Male Neutered

## AGE

8.10 years

## WEIGHT

14.58lbs

## INTERPRETED BY

Maggie Machen Lamy,  
DVM, DACVIM  
(Cardiology)

## IMAGING PERFORMED BY

Ashley Whitesell

## HOSPITAL NAME

Dicksib Animal Clinic

## REFERRING VET

Dr. Hovis

## INVOICE

46304

## DATE

1/6/26

Anesthetic risk is considered mildly elevated; however, judicious fluid administration is advised if needed with careful monitoring to screen for fluid overload. A reasonable protocol includes opioid/benzodiazepine premedication, propofol induction, isoflurane maintenance. Avoid ketamine, telazol, acepromazine and Dexdomitor. Additionally, drugs that stimulate heart rate should be avoided unless clinically necessary (glycopyrrolate, atropine).

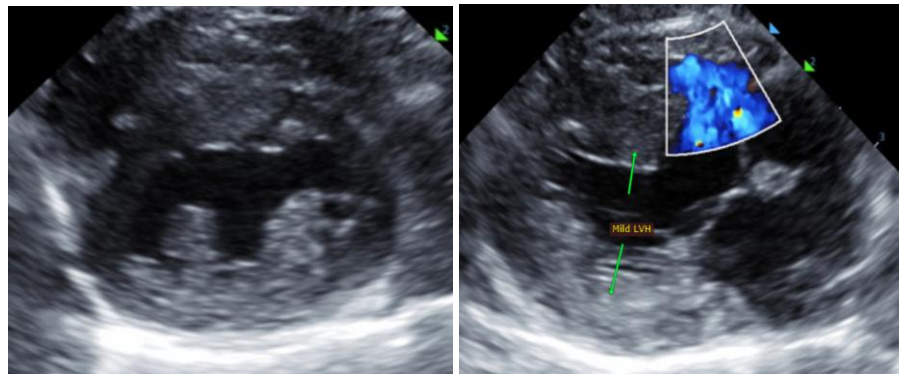
Risk for complication with steroid or fluid use typically follows LA dilation, which in this case is mildly elevated. If needed for QOL/asthma, it is reasonable to continue the medication with monitoring of RR/RE advised.

## PLAN

A screening blood pressure and T4 are recommended every 6 months lifelong.

A recheck echocardiogram is recommended in 6 months to assess for progression, sooner if any issues arise in the interim.

## IMAGES



The information and recommendations provided are based on the images presented by the referring veterinarian. No evaluation can be communicated regarding pathology that was not visible in the image/video clips provided.

Thank you for this referral. This report was generated using transcription software, and minor dictation errors may be present. If the clinical or image interpretation does not parallel your findings or if I can be of any further assistance, please contact me.

Maggie Machen Lamy, DVM  
Diplomate of the American College of Veterinary Internal Medicine (Cardiology)  
info@sonopath.com